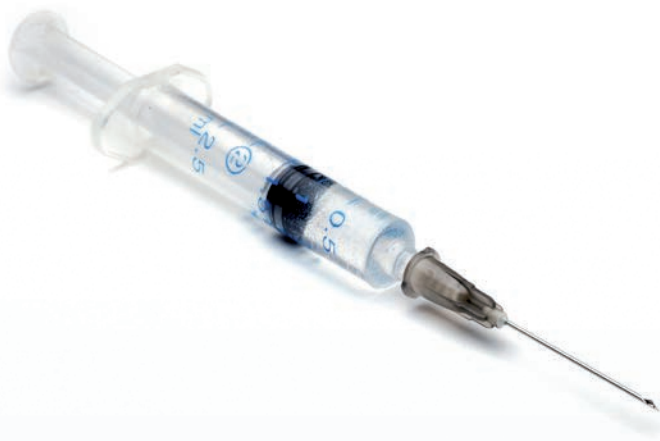


# GLUBRAN<sup>®</sup>2

CE 0373

**SYNTHETIC  
SURGICAL GLUE**



# CHARACTERISTICS

Synthetic surgical glue **Glubran 2** is a medical device Class III CE marked for **internal and external use**.

**Glubran 2** is a **synthetic biodegradable** <sup>(1)</sup> **cyanoacrylate basis glue**, modified by the addition of a monomer synthesized by the manufacturer GEM.

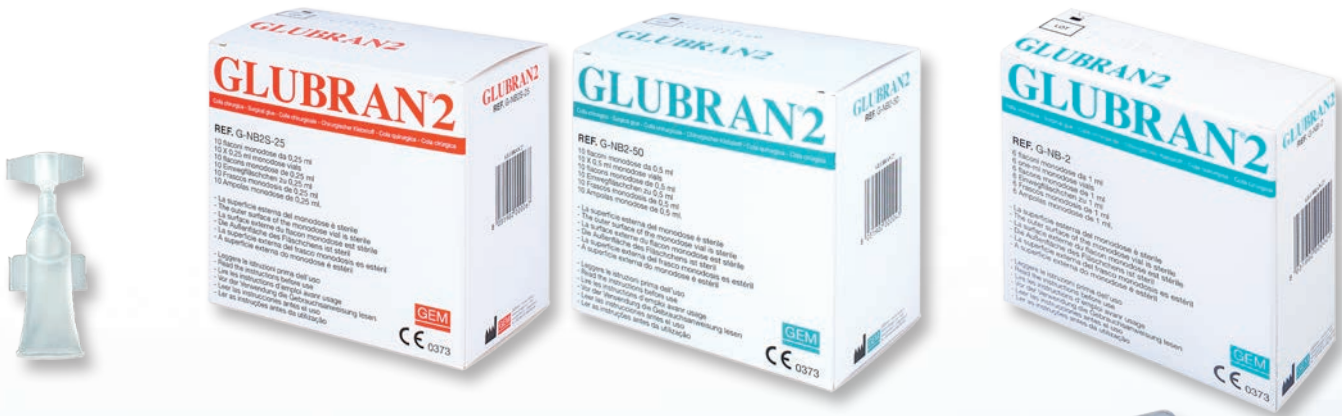**Glubran 2** is **ready for use** <sup>(2-5)</sup>. It has high **adhesive** <sup>(6)</sup> and **haemostatic** <sup>(7)</sup> **properties** and once it is polymerised it creates an **efficient antiseptic barrier** <sup>(1,8,9)</sup> against the most diffused infective or pathogenic agents during the surgical intervention.

**Glubran 2**, polymerises quickly in contact with live tissue and wet environment creating a thin and elastic film having **high tensile properties** which guarantee strong adhesion to the tissues <sup>(6)</sup>. This film naturally conforms with the tissues on which it was applied; it is **not permeable** to liquids and is not altered by blood or organic liquids <sup>(7,10)</sup>.


# INDICATIONS OF USE

**Glubran 2** is a glue which is used in **open and laparoscopic surgery** <sup>(2-5,7,8,10-64)</sup> and in **digestive tract endoscopy** <sup>(65-80)</sup>.

Furthermore **Glubran 2** is used as **embolising agent** in **radiology and vascular neuroradiology** <sup>(81-101)</sup>.



**VERSATILE**  
**EFFICIENCY**  
**RELIABILITY AT 360°**



# Biocompatible

**Total**  
**biocompatibility** (1,6,11)  
**fully proved by over**  
**20 years of studies**  
**in vivo and vitro** (1-101)

# Versatile



Cardiosurgery (5, 23-27)

Vascular Surgery (5,28)

Thoracic Surgery (29-32)

Neurosurgery (33,34)

General Surgery (2,4,7,8,10-22,35-49)

Urology (50-56)

Gynaecology (57,58)

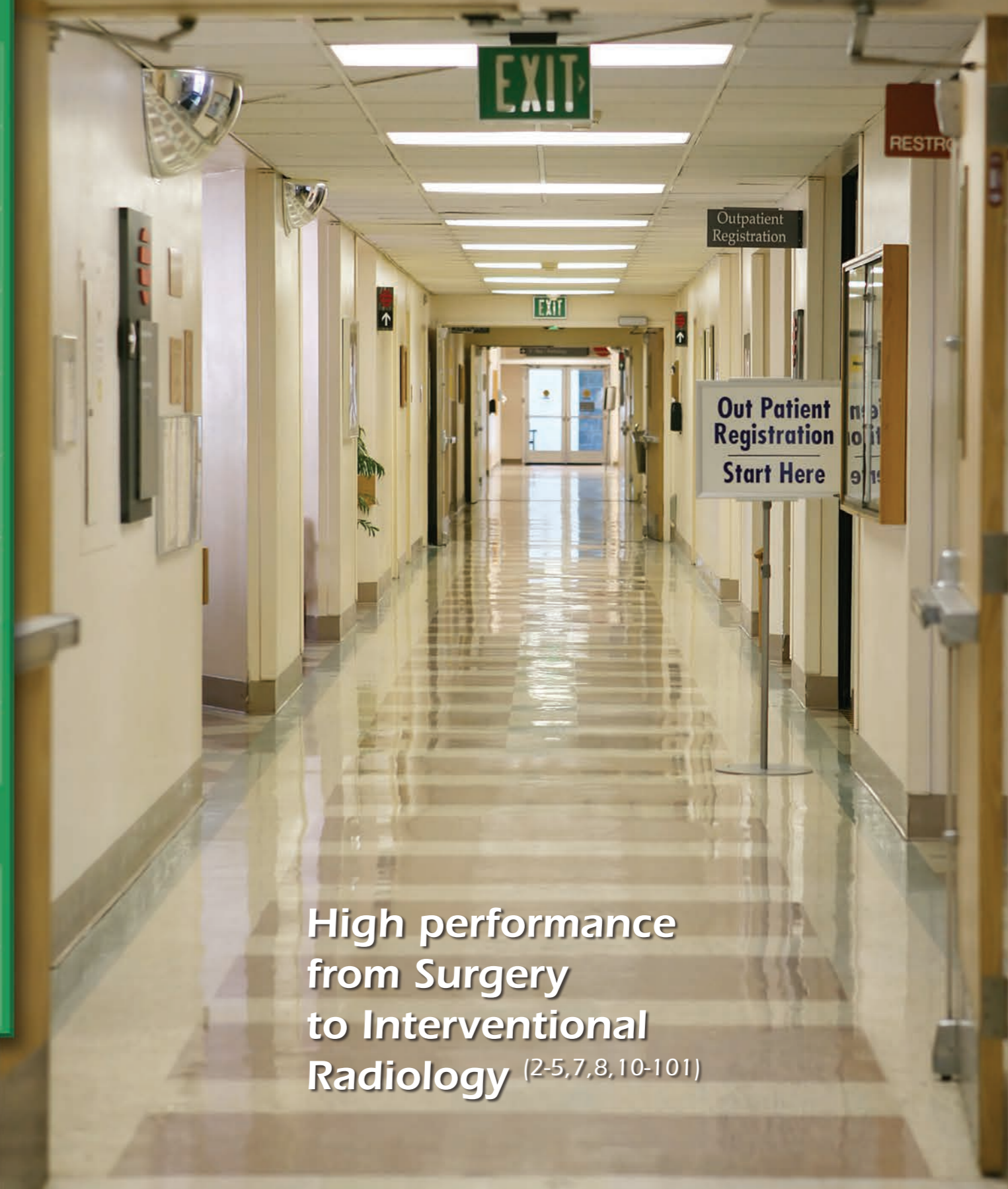ENT (59-64)

Digestive Tract Endoscopy (65-80)



Interventional Radiology (81-93)

Interventional Neuroradiology (94-101)



High performance  
from Surgery  
to Interventional  
Radiology (2-5,7,8,10-101)

# Fast

1 2 3 4 5 6 7 8

A few seconds <sup>(6,7,51)</sup>  
are enough  
to obtain  
excellent results



GLUBRAN2

# Reliable



A perfect  
mechanical  
resistance <sup>(2,6)</sup>  
is the  
guarantee to  
obtain  
reliable  
results



- 74) Repici A, Ferrari A, De Angelis C, Caronna S, Barletti C, Paganin S, Musso A, Carucci P, Debernardi-Venon W, Rizzetto M, Saracco G. **Adrenaline plus cyanoacrylate injection for treatment of bleeding peptic ulcers after failure of conventional endoscopic haemostasis.** Dig Liver Dis. 2002 May;34(5):349-55
- 75) Grassia R, Staiano T, Iiritano E, Bianchi G, Savarese M.F, Buffoli F. **Cyanoacrylate injection for treatment of non-variceal upper gastrointestinal bleeding after failure of conventional endoscopic haemostasis.** Abstracts of the 19th National Congress of Digestive Diseases / Digestive and Liver Disease 45S (2013) S55-S218
- 76) Mugnani M, Tringali A, Khodadadian E, Petruzzello L, Spada C, Spera G, Familiari P, Costamagna G. **External pancreatic fistulas resistant to conventional endoscopic therapy: endoscopic closure with N-butyl-2-cyanoacrylate (Glubran 2).** Endoscopy. 2004 Aug;36(8):738-42.
- 77) Rotondano G, Viola M, Orsini L, Cipolletta F, Bianco MA, Garofano ML, Cipolletta L. **Uncommon cause of early postoperative colonic fistula successfully treated with endoscopic acrylate glue injection.** Gastrointest Endosc. 2008 Jan;67(1):183-6.
- 78) Romano A, Spaggiari M, Masetti M, Sassatelli R, Di Benedetto F, De Ruvo N, Montalti R, Guerrini GP, Ballarin R, De Blasiis MG, Gerunda GE. **A new endoscopic treatment for pancreatic fistula after distal pancreatectomy: case report and review of the literature.** Gastrointest Endosc. 2008 Oct;68(4):798-801.
- 79) Katsanos KH, Christodoulou DK, Kamina S, Maria K, Lambri E, Theodorou S, Tsampoulas K, Vasiliki M, Tsianos EV. **Diagnosis and endoscopic treatment of esophago-bronchial fistula due to gastric heterotopy.** World J Gastrointest Endosc. 2010 Apr 16;2(4):138-42.
- 80) López J, Rodríguez K, Targarona EM, Guzman H, Corral I, Gameros R, Reyes A. **Systematic review of cyanoacrylate embolization for refractory gastrointestinal fistulae: a promising therapy.** Surg Innov. 2015 Feb;22(1):88-96.
- 81) Rossi G, Mavrogenis AF, Casadei R, Bianchi G, Romagnoli C, Rimondi E, Ruggieri P. **Embolisation of bone metastases from renal cancer.** RadiolMed. 2013 Mar;118(2):291-302.
- 82) Rossi G, Mavrogenis AF, Rimondi E, Ciccarese F, Tranfaglia C, Angelelli B, Fiorentini G, Bartalena T, Errani C, Ruggieri P, Mercuri M. **Selective arterial embolisation for bone tumours: experience of 454 cases.** RadiolMed. 2011 Aug;116(5):793-808.
- 83) Loffroy R, Guiu B, D'Athis P, Mezzetta L, Gagnaire A, Jouve JL, Ortega-Deballon P, Cheymel N, Cercueil JP, Krausé D. **Arterial embolotherapy for endoscopically unmanageable acute gastroduodenal hemorrhage: predictors of early rebleeding.** ClinGastroenterolHepatol. 2009 May;7(5):515-23.
- 84) Loffroy R, Guiu B. **Role of transcatheter arterial embolization for massive bleeding from gastroduodenal ulcers.** World J Gastroenterol. 2009 Dec 21;15(47):5889-97.
- 85) Loffroy R. **Which Acrylic Glue Should Be Used for Transcatheter Arterial Embolization of Acute Gastrointestinal Tract Bleeding?** AJR Am J Roentgenol. 2015 Oct;205(4):W465.
- 86) Urbano J, Cabrera M, Alonso A. **Usage and applicability of Cyanoacrilate monomer: further vascular malformations.** P-157, CIRSE 2009 Educational Poster;
- 87) Marcello R, Marcello G. **Glubran 2 Transcatheter Embolization of Active Gastrointestinal Hemorrhage.** Poster 26<sup>th</sup> ISET Endovascular Therapy Congress 2014 18-22 Jan, Miami USA.
- 88) Gortlitz M, Mertikian G, Trnka H, Froeschl A, Meinhart J, Weiss G, Grabenwoeger M, Rand T. **Translumbar treatment of type II endoleaks after endovascular repair of abdominal aortic aneurysm.** Interact CardiovascThorac Surg. 2008 Oct;7(5):781-4.
- 89) Favard N, Moulin M, Fauque P, Bertaut A, Favelier S, Estivalet L, Michel F, Cormier L, Sagot P, Loffroy R. **Comparison of three different embolic materials for varicocele embolization: retrospective study of tolerance, radiation and recurrence rate.** Quant Imaging Med Surg. 2015 Dec;5(6):806-14.
- 90) Loffroy R, Kretz B, Guiu B, Bouchot O, Cercueil J, Brenot R, Krausé D, Steinmetz E. **Transabdominal percutaneous embolization of a type 2B endoleak in a patient with covered abdominal aortic endoprosthesis.** J Radiol. 2010 Sep;91(9 Pt1):901-4.
- 91) Resch T, Dias N. **Treatment of endoleaks: techniques and outcome.** J Cardiovasc Surg (Torino). 2012 Feb;53(1 Suppl 1):91-9.
- 92) Gandini R, Chiochetti M, Morosetti D, Chiaravallotti A, Loreni G, Simonetti G. **Trans-caval Endoleak Embolization (TCEE) of Type I and II Endoleaks Occurring after Endovascular Abdominal Aortic Aneurysm Repair (EVAR).** C-1616 Congress: ECR 2012
- 93) Coppi G, Saitta G, Coppi G, Gennai S, Lauricella A, Silingardi R. **Transealing: a novel and simple technique for embolization of type 2 endoleaks through direct sac access from the distal stent-graft landing zone.** Eur J VascEndovasc Surg. 2014 Apr;47(4):394-401.
- 94) Leonardi M, Barbara C, Simonetti L, Giardino R, Aldini NN, Fini M, Martini L, Masetti L, Joehler M, Roncaroli F. **Glubran 2: a new acrylic glue for neuroradiological endovascular use. Experimental study on animals.** Interv Neuroradiol. 2002 Sep 30;8(3):245-50.
- 95) Leonardi M, Cenni P, Simonetti L, Bozzao A, Romano A, Bonamini M, Fantozzi LM, Fini G. **Glubran 2: a new acrylic glue for neuroradiological endovascular use: complementary histological study.** IntervNeuroradiol. 2003 Sep 30;9(3):249-54.
- 96) Raffi L, Simonetti L, Cenni P, Bandiera S, Gasbarrini A, Boriani S, Leonardi M. **Presurgical embolization of spinal tumours using Glubran 2 acrylic glue.** IntervNeuroradiol. 2003 Dec 20;9(4):339-49.
- 97) Law-ye B, Clarençon F, Sourour NA, Di Maria F, Jean B, Bonneville F, Biondi A, Iosif C, Navarro S, Cornu P, Chiras J. **Risks of presurgical embolization of feeding arteries in 137 intracranial meningeal tumors.** Acta Neurochir (Wien). 2013 Apr;155(4):707-14.
- 98) Abud DG, Mounayer C, Benndorf G, Piotin M, Spelle L, Moret J. **Intratumoral injection of cyanoacrylate glue in head and neck paragangliomas.** AJNR Am J Neuroradiol. 2004 Oct;25(9):1457-62.
- 99) Li ZR, Jiang ZB, Huang MS, Zhu KS, Wang Q, Shan H. **Transvenous embolization of cavernous sinus dural arteriovenous fistulas using detachable coils and Glubran 2 acrylic glue via the inferior petrosal sinus approach.** EurRadiol. 2010 Dec;20(12):2939-47.
- 100) Desal HA, Toulgoat F, Raoul S, Guillon B, Al Hammad Ibrahim R, Auffray-Calvier E, De Kersaint-Gilly A. **Brain arteriovenous malformations technical note of endovascular treatment with glubran(r).** IntervNeuroradiol. 2005 Oct 5;11(Suppl 1):125-30.
- 101) Liu J, Lv M, Lv X, He H, Liu A, Qian Z, Li Y. **Curative Glubran 2 embolization of cerebral arteriovenous malformations patient selection and initial results.** IntervNeuroradiol. 2014 Dec;20(6):722-8.

GEM was born in 1994 with the goal of marketing new surgical adhesives.

Permanent research is the basis of our work and our aim is to produce innovative surgical adhesives in order to anticipate the requests of an ever more sophisticated market.

The synthetic surgical glue Glubran 2 obtained the **CE CERTIFICATION** released by the Notify Body 0373 (**Istituto Superiore della Sanità**) in 1998.

GEM srl obtained the following **Quality Certifications** released by **TUV Product Service** in 2006:

EN ISO 13485:2012

UNI EN ISO 9001:2008

TUV America Inc ISO 13485:2003



Ed. 01/02/2016 Rev 01

**GLUBRAN<sup>2</sup>**





Via dei Campi 2 - PO Box 427 - 55049 Viareggio (LU) Italy  
Tel. +39 0584 389784/391388 - Fax +39 0584 397904  
[www.gemitaly.it](http://www.gemitaly.it) - [info@gemitaly.it](mailto:info@gemitaly.it)